

Refining Vertical Lobule Division in Open Septorhinoplasty

Etai Funk, MD; Nitin Chauhan, MD; Peter A. Adamson, MD, FRCSC

Objective: To review the indications, surgical techniques, and results of vertical lobule division (VLD) of the alar cartilages as they relate to the M-Arch Model.

Design: Retrospective study of patients who underwent VLD of the lower lateral cartilages at a private facial plastic surgery practice in a major university teaching hospital.

Results: Vertical lobule division decreased projection in 34 of 41 patients, narrowed a wide or boxy tip in 25, corrected knuckling or bossae in 20, corrected tip asymmetry in 14, corrected a hanging columella in 14, in-

creased rotation in 12, and decreased rotation in 6. No statistically significant correlation was noted between the location of VLD and the indication for which it was performed. One patient required revision surgery to increase rotation.

Conclusions: Vertical lobule division remains a reliable and safe technique with predictable outcomes in tip repositioning. It allows for preservation of a strong tip complex, while adding versatility to tip refinement.

Arch Facial Plast Surg. 2009;11(2):120-125

NASAL TIP REFINEMENT IS possibly the most difficult aspect of rhinoplasty. Vertical lobule division (VLD) is a powerful and versatile technique for changing the configuration of the nasal tip. Our level of knowledge and sophistication about the nasal tip has evolved notably with the popularization of open rhinoplasty,¹ which has allowed surgeons to realize the broad applicability of VLD.

Vertical lobule division can occur anywhere between the medial crural angle (the junction of the medial and intermediate crura) and the lateral crural angle. *Medial crural angle* is a well-recognized term and defines the ill-defined junction of the medial and intermediate crura, which is approximately at the level of the nostril apex. *Lateral crural angle* is a new anatomic term we hereby define as that ill-defined junction of the anterior lobular portion of the lower lateral crus and its more posterior alar component. It too is approximately at the level of the nostril apex. Goldman² first described this technique in 1957 as making the division lateral to the domes. This technique involved incising the lateral crura and vestibular skin and allowing the medial segments to be advanced anteriorly and sewn together to increase tip projection

and rotation. This converted a trapezoidal tip into a pyramidal one. It was a controversial technique because it weakened the M-arch, resulting in bossa, knuckling, asymmetries, and tip irregularities in some patients, especially in those with thin skin due to the wound contracture. The source of the potential undesired sequelae lies in the discontinuous weakened lower lateral cartilage. Over the years, modifications have been made to the Goldman technique, and it is still used effectively by some surgeons.³

To avoid these tip abnormalities, the Goldman technique evolved to become VLD. However, VLD does not increase projection as in the Goldman technique but decreases it by overlapping the cartilage to reinforce the divided cartilage. Vertical lobule division approximates the medial, intermediate, and lateral crura to prevent any displacement or malposition.

METHODS

NASAL TIP DYNAMICS

To fully grasp the technique and applicability of VLD, one must have a good understanding of nasal tip dynamics. The curvature in the conjoined medial and intermediate crura, opposed by the curvature in the lateral crura (**Figure 1**), creates tension in the M-arch struc-

Author Affiliations: Division of Facial Plastic and Reconstructive Surgery, Department of Otolaryngology–Head and Neck Surgery, University of Toronto, Toronto, Ontario, Canada.

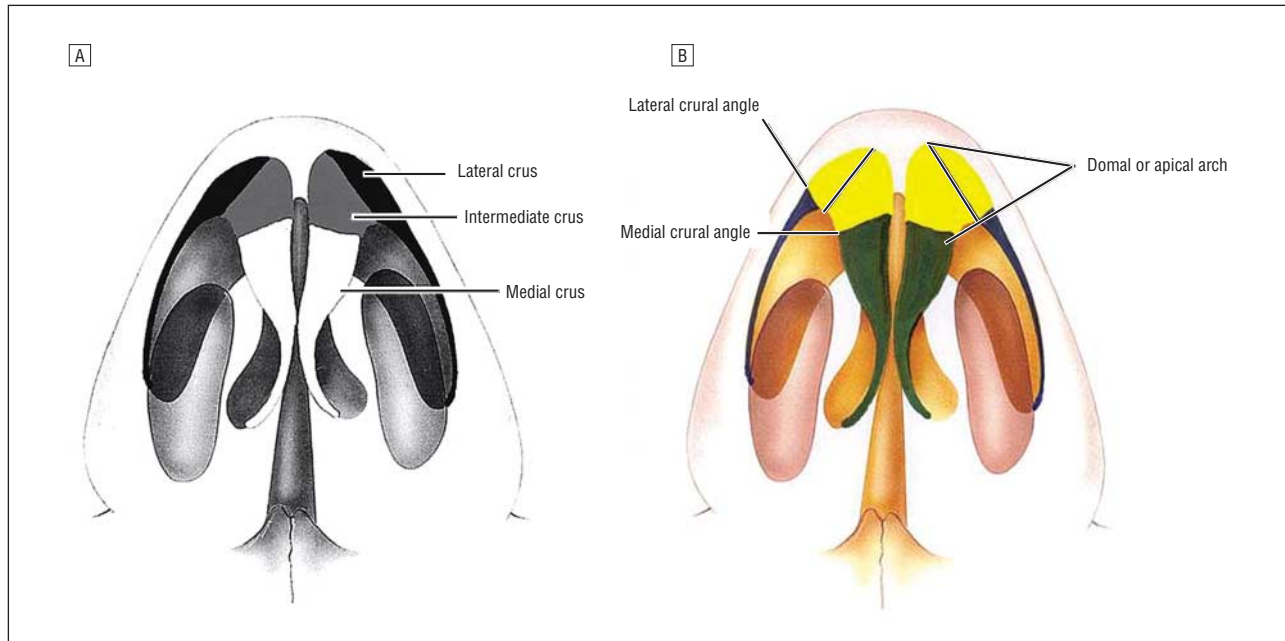


Figure 1. Nasal tip dynamics. A, The M-arch consists of the conjoined medial and intermediate crura and the bilateral lateral crura. B, For the lobular arch, the domal (or apical) arch is formed unilaterally by the intermediate crus, anterior aspect of the lower lateral cartilage, and external and internal soft-tissue triangles. The conjoined domal arches constitute the lobular arch.

ture, somewhat like a “sprung horseshoe.” The anterior tension in the lower lateral crura makes them project the nasal tip, thrusting it anteriorly and inferiorly. The medial and intermediate crura counteract this with an anterior and superior thrusting motion (**Figure 2**). Soft tissue and ligaments contribute to the balance achieved between these opposing forces, determining the tip-defining point in space and the nasal variables of length, projection, and rotation.

The tripod concept as described by Anderson⁴ envisions the conjoined medial crura as forming 1 leg of a tripod and each of the lower lateral crura as forming the other 2 legs. The tripod concept allows one to conceptualize maneuvers that will alter tip projection, rotation, and nasal length by shortening the medial and lateral crura.

The M-Arch Model has been devised as a modern and more sophisticated extension of the tripod concept, with broader applications relative to the major nasal variables of length, projection, and rotation. It also integrates maneuvers to create ideal lobule definition.^{5,6} Within the M-arch are the paired domal arches, which together constitute the lobular arch. The domal arch is formed unilaterally by the intermediate crus, anterior aspect of the lower lateral crus, external soft-tissue triangle, and internal soft-tissue triangle. It is also sometimes called “the apical arch.”

Whereas the tripod concept predicts a uniform effect on tip rotation and projection for a given shortening maneuver, the M-Arch Model recognizes that an equal amount of shortening or lengthening of the M-arch may produce variable, yet predictable, changes in these nasal variables depending on where the shortening, or alternatively the lengthening, is performed. For example, shortening the medial crura will cause deprojection and counterrotation, whereas shortening the lateral crura will cause deprojection and rotation. Shortening the intermediate crus will cause a variable degree of deprojection and rotation depending on where vertical division and overlap are performed. If performed near the medial crural angle at the junction of the medial and intermediate crura, there will be more deprojection and less rotation. If performed closer to the apex of the domal arch, there will be more rotation and less deprojection.

The M-Arch Model further recognizes that these changes can affect lobular refinement, which is unaddressed in the initial tri-

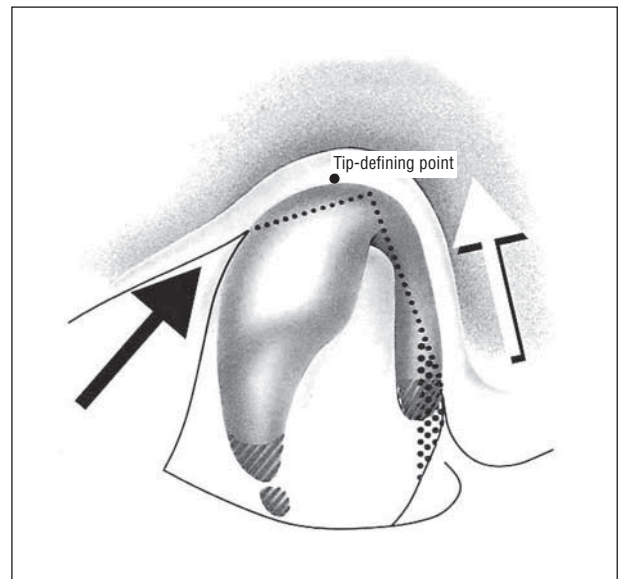


Figure 2. Dynamics of the M-arch showing the thrusting forces (arrows) that define the dynamics of the lower lateral cartilages.

pod concept. For example, shortening the intermediate crura will shorten the length of the infratip lobule and increase the angle of the domal arch, rounding the external soft-tissue triangle. If vertical division of the intermediate crus is performed near the angle or junction of the medial and intermediate crura, a hanging infratip lobule can be reduced. If performed near the apex of the domal arch, a boxy or biconvex lobular arch can be narrowed.

INDICATIONS FOR VLD

Vertical division of the M-arch with overlapping suture stabilization of the divided segments provides the most desirable and effective outcome.⁷ The location for arch division is dependent

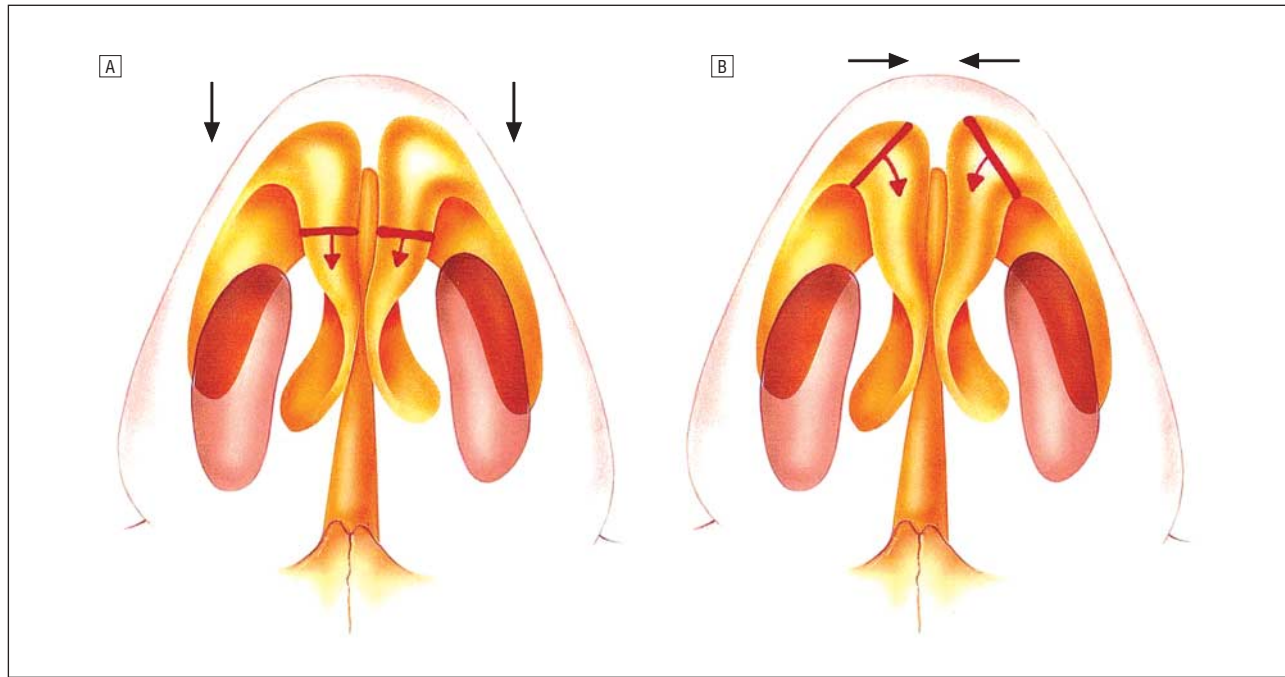


Figure 3. How vertical lobular division can alter the lobule. A, The overlap is performed in the domal arch where there is a significant vertical component to the arch, causing decreased projection. B, The overlap is performed where there is a significant horizontal component to the domal arch, causing arch and lobule narrowing.

on the desired result. Vertical lobule division is useful for decreasing nasal tip projection, increasing or decreasing rotation, narrowing a wide domal arch, correcting asymmetries, improving a hanging infratip lobule, and correcting an elongated lobule-nostril relationship. We have found VLD to be most useful in the overprojected inferiorly rotated tip because overlapping the cut segments results in deprojection, rotation, or both.

The open approach allows the best exposure and visualization of the tip to perform VLD. However, VLD may also be performed using an endonasal approach with tip delivery and applying these same concepts.

When the lobular contour is asymmetrical, vertical division within the domal arch segment may be used to simultaneously correct the M-arch length and asymmetry in addition to irregularities of the lobular-columellar relationship such as a hanging infratip. Vertical lobule division may also be performed unilaterally, or bilaterally but asymmetrically, as required to achieve ideal shape and symmetry. Vertical arch divisions are ideally performed within the intermediate crus so that the overlap is concealed in the infratip region after surgery. This overlap also acts to strengthen any weakened, knuckled, or buckled cartilage. Division nearest the angle of the medial and intermediate crura will produce deprojection and vertical M-arch shortening without substantively affecting lobular width or rotation (**Figure 3A**). Conversely, division nearest the tip-defining point will primarily achieve M-arch shortening with narrowing of the lobule (**Figure 3B**).

PROCEDURE

The open approach is used to accurately assess the tip anatomy and to precisely perform VLD. The vestibular skin is widely undermined in the area of intended division. Using calipers, the point of division is selected, and the amount of cartilage overlap is measured and marked. After the division is made, the lateral segment is placed over the medial segment to conceal this overlap in the infratip area. At least 3 mm of overlap is necessary to obtain an appreciable result. In addition, it is more dif-

ficult to technically reapproximate an overlap less than 3 mm. It is also unusual to overlap more than approximately 6 mm at most. A 6-0 nylon horizontal mattress suture is first placed to establish the amount of overlap and to reconstitute the cartilage. Care is taken not to catch any vestibular skin and to bury the knot between the medial crura. A second 6-0 nylon suture is placed to reestablish the desired longitudinal axis of the overlapped cartilages. If substantial overlap (>5 mm) is required, it is sometimes facilitated technically by excising a small portion of the overlapped cartilage, always leaving at least 3 to 4 mm of cartilage overlap to suture. **Figure 4** shows a series of intraoperative photographs illustrating VLD.

When a columellar strut is also being placed, it is usually best to first elevate the vestibular skin in preparation for VLD, place the columellar strut using a 10-mm sharp hook to anteriorly displace the apices of the domal arches to maintain bilateral symmetry while placing columellar transfixion sutures, and then perform VLD. In this way, the nasal base can be built from the spine upward, creating a strong and symmetrical foundation as the reconstruction proceeds toward the lobule. In cases of asymmetrical domal arches, a variable amount of cartilage can be overlapped on each side to obtain improved symmetry. Weakened or knuckled cartilages are also strengthened by the overlap, which doubles the crural thickness in the overlapped region. Further structural support is obtained by placing an intermediate crural horizontal mattress suture, which stabilizes the medial and intermediate crura by spanning the actual crural division. In the infrequent situation in which the newly formed intermediate crura are still weak or crooked, the columellar strut can be extended farther cephalad or a second strut placed vertically between the intermediate crura.

RESULTS

Forty-one patients underwent open septorhinoplasty with VLD performed by one of us (P.A.A.) from January 1, 2002, to December 31, 2007. There were 36 women and

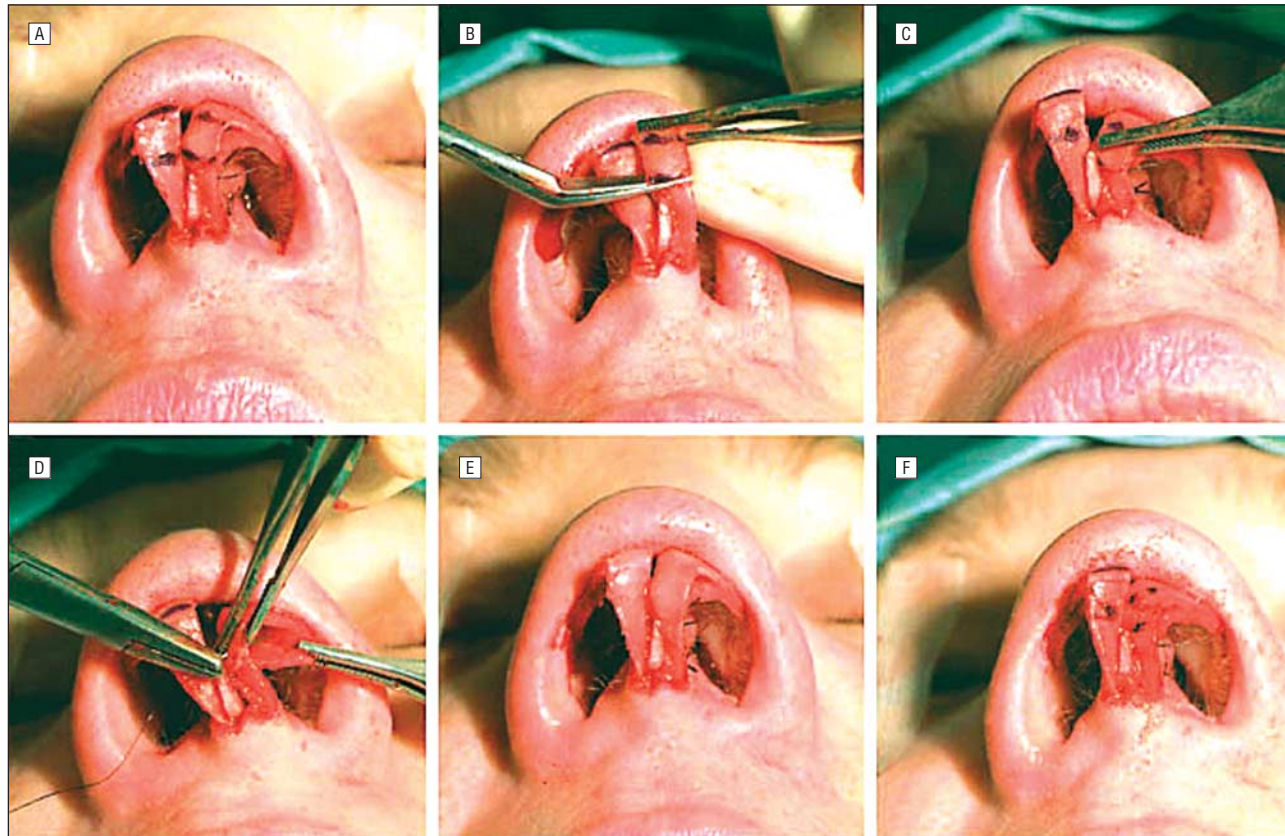


Figure 4. Sequence of steps in vertical lobular division (VLD). A, The site of VLD is marked. B, Scissors cut through the lower lateral cartilage. C, The overlapped cartilage ends. D, The overlapped ends are sutured. E, Basal view before VLD. F, Basal view after VLD (left side only).

Table. Location of Vertical Lobule Division vs Indication for Performing the Technique Among 41 Patients

| Indication | No. (%) | | | |
|--------------------------------------|---------------------|-----------------------|-------|----------------|
| | Medial Crural Angle | Mid Intermediate Crus | Dome | Total |
| Overprojection | 23 (56) | 8 (20) | 3 (7) | 34 (83) |
| Bulbous or wide tip | 16 (39) | 6 (15) | 3 (7) | 25 (61) |
| Knuckling or bossae | 13 (32) | 5 (12) | 2 (5) | 20 (49) |
| Asymmetry | 9 (22) | 3 (7) | 2 (5) | 14 (34) |
| Hanging or elongated infratip lobule | 8 (20) | 4 (10) | 2 (5) | 14 (34) |
| Underrotation | 5 (12) | 6 (15) | 1 (2) | 12 (29) |
| Overrotation | 5 (12) | 1 (2) | 0 | 6 (15) |

5 men, with a mean age of 32 years. Twenty-eight patients underwent primary rhinoplasty, and 13 patients had revisions. Thirty-nine patients had bilateral divisions of the vertical lobule, and 2 patients had unilateral divisions (both underwent revision rhinoplasties). The mean amount of overlap for VLD was 4.2 mm. Twenty-six of 41 divisions (63%) were performed at the angle, 12 (29%) in the midportion of the intermediate crus, and 3 (7%) at the dome area. Most patients had multiple indications for VLD, including the following: to decrease projection (34 of 41 [83%]); to narrow a wide, bulbous, or boxy tip (25 [61%]); to correct knuckling, bossae, or a pinched tip (20 [49%]); to correct asymmetries (14 [34%]); to address a hanging columella (14 [34%]); to increase rotation (12 [29%]); and to decrease rotation (6 [15%]). The **Table** gives the location of each type of VLD

in relation to the indication for which it was performed. Using the Fisher exact test, no statistically significant correlation was noted between the location of VLD and the indication for which it was performed. One patient did not attain the desired rotation after VLD and required revision surgery with a lateral crural flap and overlay, giving a revision rate of 2.4%.

COMMENT

One of us (P.A.A.) has written extensively on the topic of VLD.^{7,8} One hundred sixteen patients in a previous study⁷ were divided into those who had cartilage excised (75 patients), which was the technique used before 1987, and those who had cartilage overlapped (41 patients). The excision group had a higher rate of revision surgery than the over-

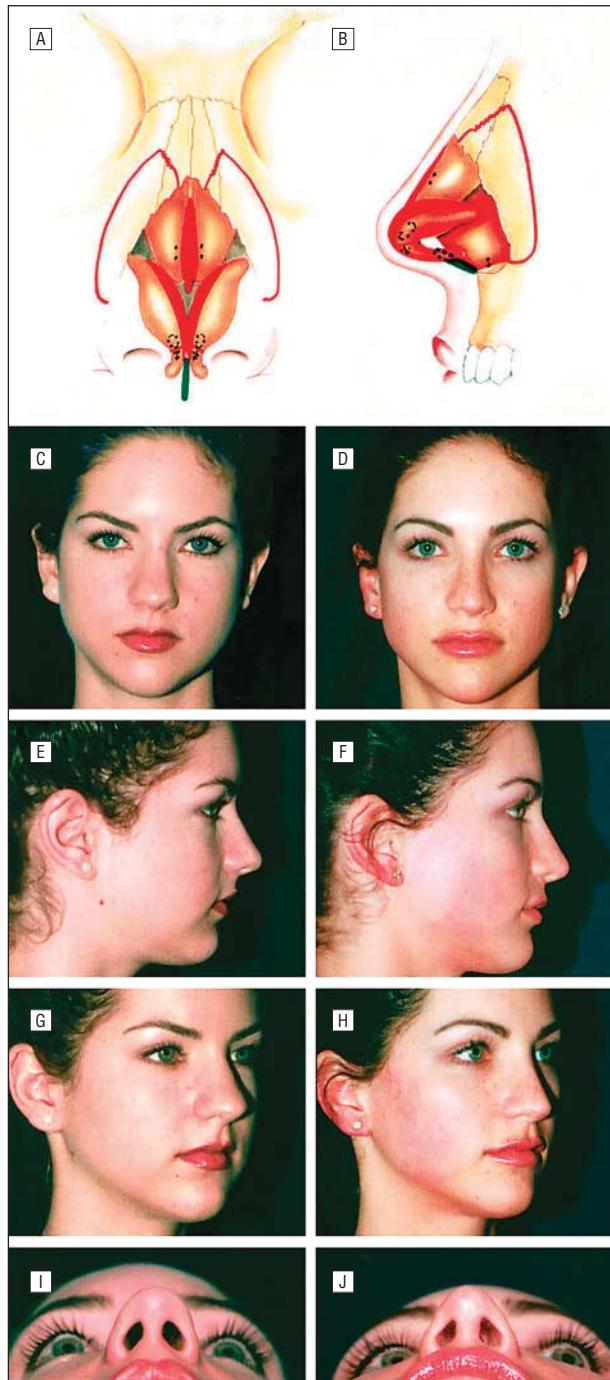


Figure 5. Views during surgery (A and B), before surgery (C, E, G, and I), and after surgery (D, F, H, and J). A and B, Vertical lobule division and single-dome unit suture placement are performed for deprojection and lobule refinement. Views before and 30 months after rhinoplasty include frontal (C and D), right lateral (E and F), right oblique (G and H), and basal (I and J). Published previously in the Jan/Feb 2006 issue of the *Archives*⁵ and reprinted herein with permission.

lap group (4.0% vs 2.4%). Using the overlap technique for VLD, the present study demonstrated an identical revision rate of 2.4%. This reinforces the strength of this technique as a time-honored and dependable maneuver that is capable of consistent and reproducible results.

The versatility of VLD allows changes in projection, rotation, and width of the domal arch, as well as correction

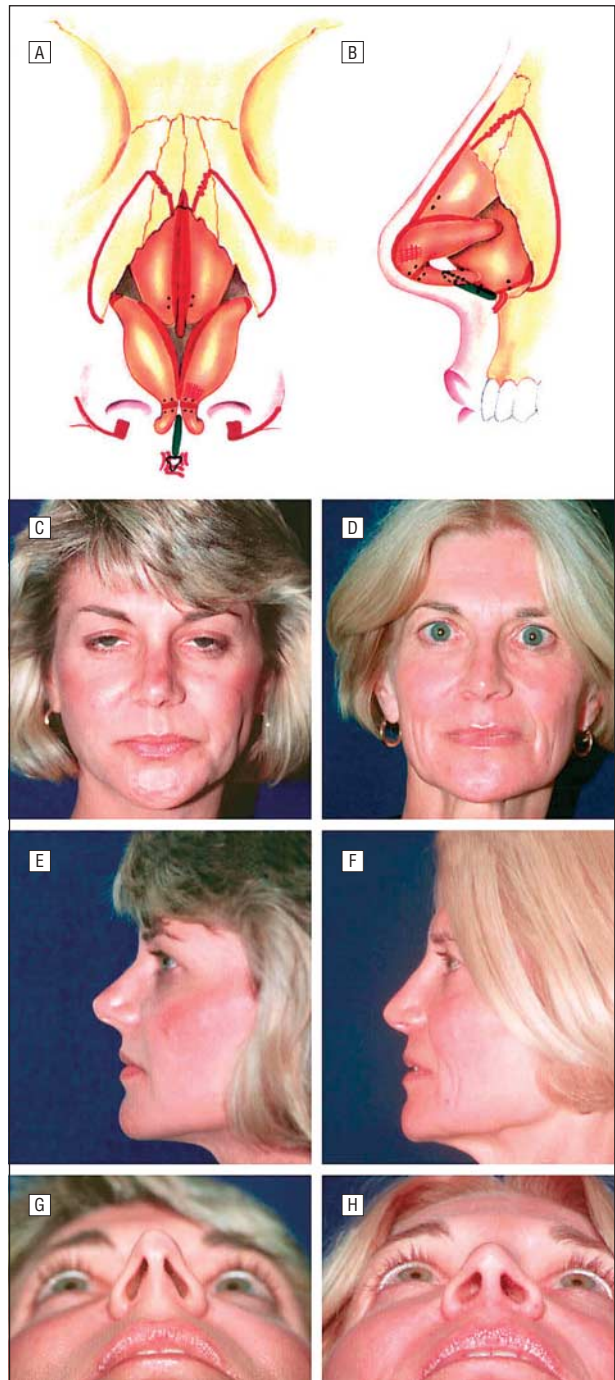


Figure 6. Views during surgery (A and B), before surgery (C, E, and G), and after surgery (D, F, and H). A and B, Vertical lobule division and hinge setback are performed for deprojection and correction of retrusé tip. Views before and 16 years after rhinoplasty include frontal (C and D), left lateral (E and F), and basal (G and H). Published previously in the Jan/Feb 2006 issue of the *Archives*⁵ and reprinted herein with permission.

of lobule asymmetries and a hanging or elongated infratip lobule. By using an overlap technique with suture stabilization, postoperative tip abnormalities can be avoided, and a strong and refined M-arch can be attained.

Possible disadvantages of VLD include disruption and weakening of the alar cartilages and increased operative time required for elevating the vestibular skin and proper

overlapping of the cartilages. However, by overlapping these cartilages, the crura are given increased strength and support for the nasal tip.

Although we prefer open septorhinoplasty for VLD, it can be performed using an endonasal technique. However, this may be more technically challenging. Simons³ demonstrated that VLD is a conservative approach that is incisional rather than excisional (which can lead to postoperative irregularities). Simons used a delivery approach after marginal incisions. Brennan⁹ also described good results using an endonasal technique.

In our study, the most common indication for VLD was to decrease projection. This is typically accomplished by performing VLD and overlap at the angle. However, VLD can be performed for multiple indications in the same patient, which is evident in this study. In fact, this is what makes the maneuver so flexible and versatile. **Figure 5** and **Figure 6** show patient examples using VLD.

We were unable to demonstrate statistical significance between the indication for VLD and the location where it was performed. This can be explained by several reasons. Because each patient had multiple indications for VLD, the location was likely chosen for the variable that needed the most improvement. For example, if a patient had an extremely long infratip lobule but a mildly bulbous tip, VLD would likely be performed at the angle to address the infratip lobule. The bulbous tip could be addressed using other maneuvers such as alar strut grafts, suturing techniques, and cephalic trimming of the lower lateral cartilage. Forty-one patients may represent an insufficient sample to demonstrate significant correlation between the location of VLD and the indication for which it was performed. Future studies evaluating more patients may allow us to effectively demonstrate a positive correlation between these variables.

In summary, vertical lobule division remains a powerful, flexible, and proven maneuver for correcting tip abnormalities and irregularities. Using the overlap technique, tension is removed from the M-arch, and more strength is given to the cartilage. This allows one to

address knuckling, asymmetries, infratip lobules, nasal overprojection, and problems with rotation. These can be corrected with great precision and predictability using this technique.

Accepted for Publication: October 1, 2008.

Correspondence: Peter A. Adamson, MD, FRCSC, Division of Facial Plastic and Reconstructive Surgery, Department of Otolaryngology–Head and Neck Surgery, University of Toronto, c/o Adamson and Associates, 150 Bloor St W, Ste M110, Toronto, ON M5S 2X9, Canada (paa@dradamson.com).

Author Contributions: *Study concept and design:* Funk, Chauhan, and Adamson. *Acquisition of data:* Funk and Chauhan. *Analysis and interpretation of data:* Funk. *Drafting of the manuscript:* Funk and Chauhan. *Critical revision of the manuscript for important intellectual content:* Funk, Chauhan, and Adamson. *Statistical analysis:* Funk and Chauhan. *Administrative, technical, and material support:* Funk, Chauhan, and Adamson. *Study supervision:* Funk and Adamson.

Financial Disclosure: None reported.

REFERENCES

1. Goodman WS. External approach to rhinoplasty. *Can J Otolaryngol.* 1973;2(3):207-210.
2. Goldman IB. Panel: questions and answers on rhinoplasty. *Eye Ear Nose Throat Mon.* 1957;36(8):476-477.
3. Simons RL. Vertical dome division in rhinoplasty. *Otolaryngol Clin North Am.* 1987; 20(4):785-796.
4. Anderson JR. A new approach to rhinoplasty. *Trans Am Acad Ophthalmol Otolaryngol.* 1966;70(2):183-192.
5. Adamson PA, Litner JA, Dahiya R. The M-Arch Model: a new concept of nasal tip dynamics. *Arch Facial Plast Surg.* 2006;8(1):16-25.
6. Adamson PA, Litner JA. Applications of the M-Arch Model in nasal tip refinement. *Facial Plast Surg.* 2006;22(1):42-48.
7. Adamson PA, McGraw-Wall BL, Morrow TA, Constantinides MS. Vertical dome division in open rhinoplasty: an update on indications, techniques, and results. *Arch Otolaryngol Head Neck Surg.* 1994;120(4):373-380.
8. Constantinides M, Liu ES, Miller PJ, Adamson PA. Vertical lobule division in rhinoplasty: maintaining an intact strip. *Arch Facial Plast Surg.* 2001;3(4):258-263.
9. Brennan HG. Dome-splitting technique in rhinoplasty with overlay of lateral crura. *Arch Otolaryngol.* 1983;109(9):586-592.

Announcement

Visit www.archfacial.com. As an individual subscriber you can organize articles you want to bookmark using My Folder and personalize the organization of My Folder using folders you create. You can also save searches for easy updating. You can use My Folder to organize links to articles from all 10 JAMA and Archives journals.